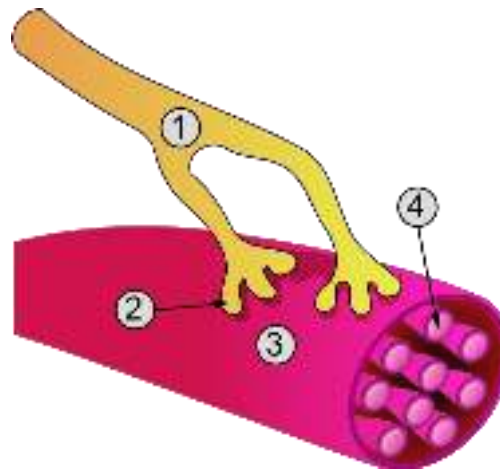


SISTEMUL MUSCULAR

Partea activa a aparatului locomotor



TIPURI DE MUSCULATURA

- STRIATA – muschii scheletici
 - > se afla sub control voluntar
- NETEDA – muschi din componenta organelor interne
 - > nu poate fi controlata voluntar

!AU PROPRIETATEA SPECIFICA DE A TRANSFORMA ENERGIA CHIMICA IN ENERGIE MECANICA

PROPRIETATILE MUSCHILOR

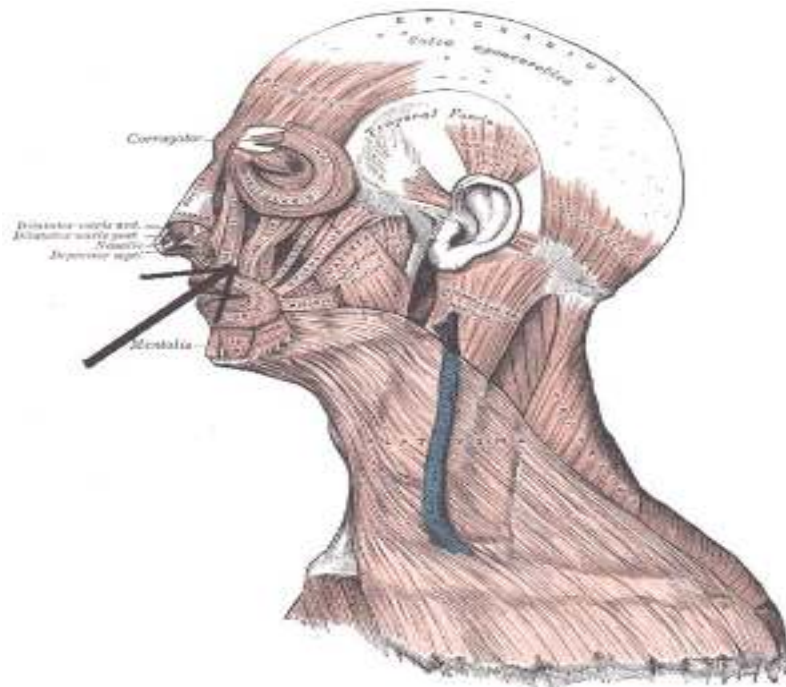
- CONTRACTILITATEA - Capacitatea de a se scurta
- EXCITABILITATEA - Capacitatea de a raspunde la un impuls nervos printr-o contractie
- ELASTICITATEA – capacitatea de a se deforma sub actiunea unei forte si de a reveni la forma de repaos cand forta a incetat
- TONUSUL MUSCULAR – o stare de semicontractie permanenta

CONTRACTIA MUSCULARA

- Se produce prin culisarea miofilamentelor de actina si miozina, la nivelul sarcomerului
- Necesita un impuls nervos transmis la nivelul sinapsei neuro-musculare (mediatorul chimic este acetilcolina)
- Ionii de calciu sunt implicati in contractie

MUSCHII CAPULUI

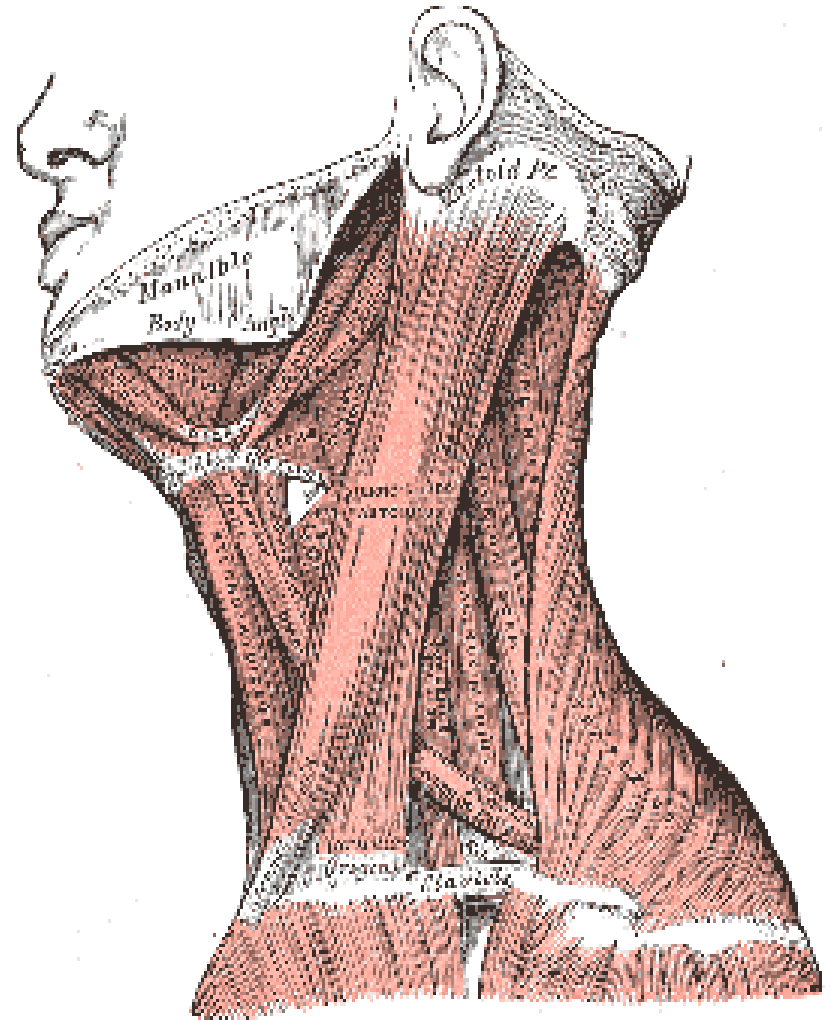
- MUSCHII MIMICII (12)
 - se insera cu un capat pe piele (muschi cutanati)
 - se grupeaza in jurul orificiilor bucal, orbitale, nazal
- MUSCHII MASTICATORI (4)
 - Se insera cu un capat pe oasele bazei craniului si cu celalalt pe mandibula



MUSCHII GATULUI

regiunea antero-laterală

- PLATISIMA – imediat sub piele
- STERNOCLEIDOMASTOIDIAN – între clavicula și stern
- SUPRAHIOIDIENI
- INFRAHIOIDIENI
- SCALENI
- PREVERTEBRALI

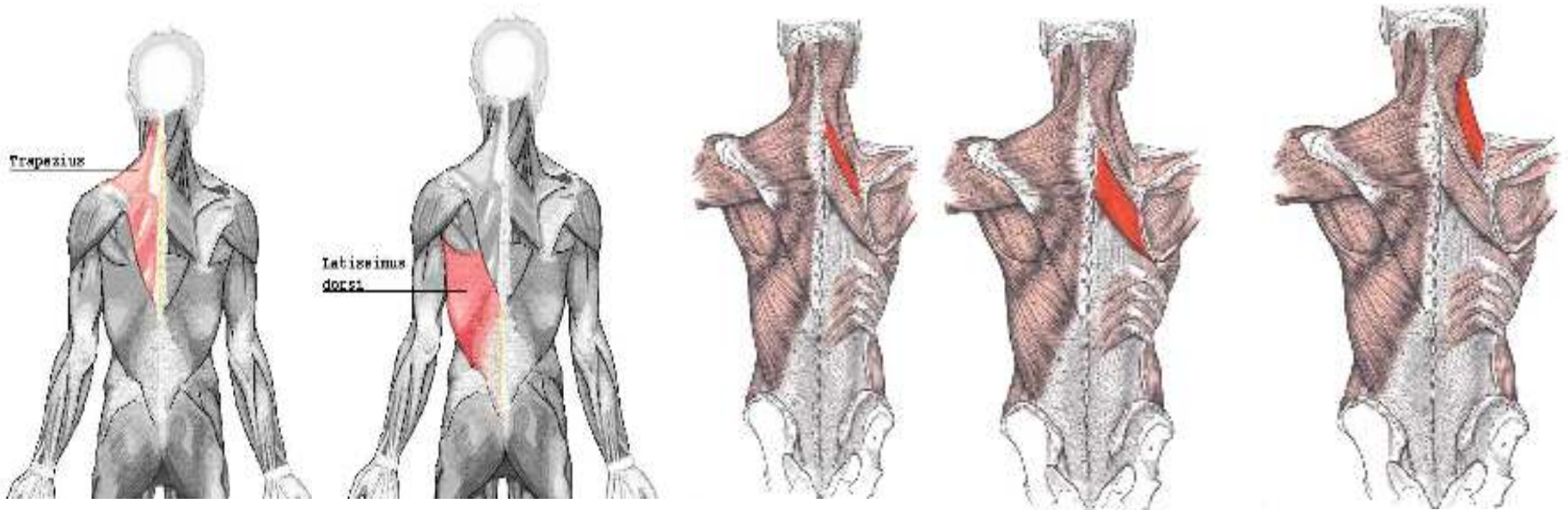


MUSCHII TRUNCHIULUI

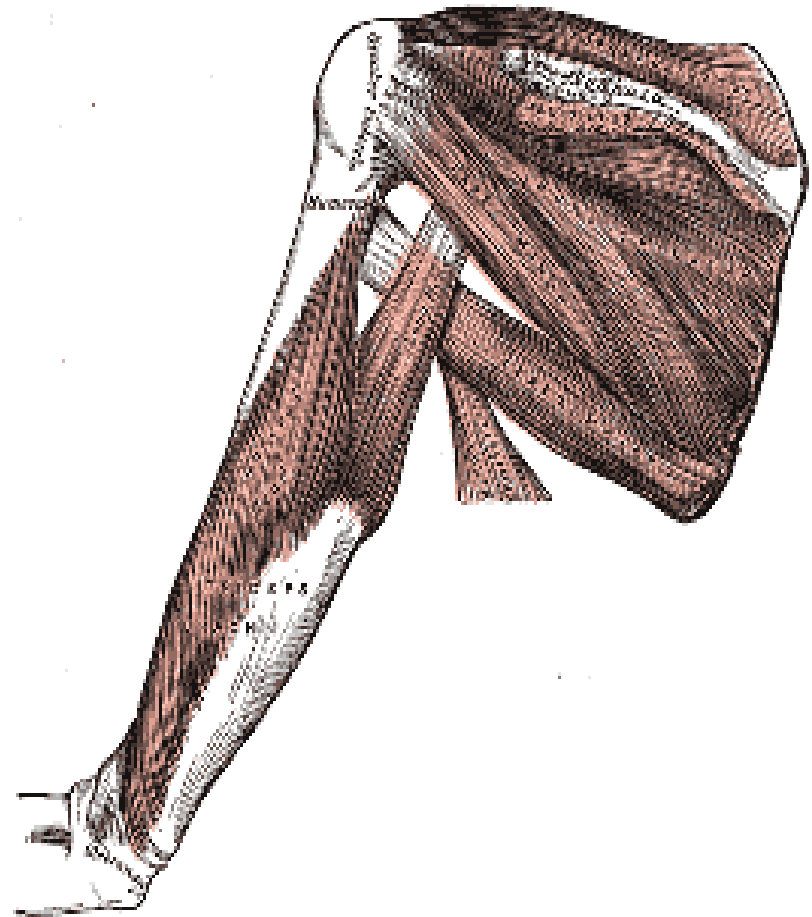
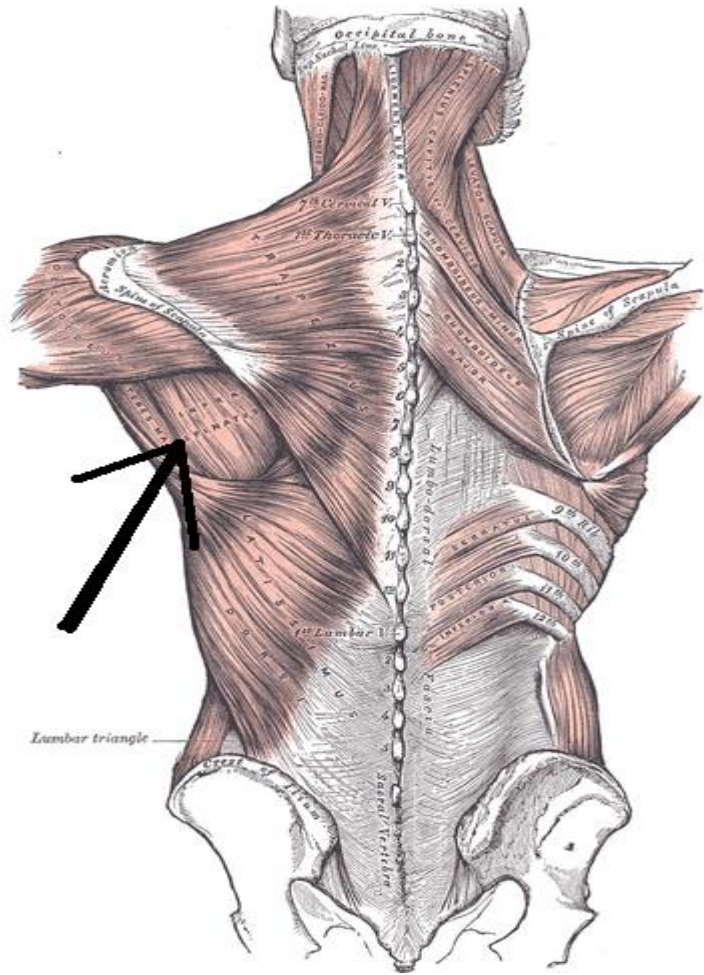
- MUSCHII SPATELUI SI CEFEI
- MUSCHII ANTERO-LATERALI AI TORACELUI
- MUSCHII ANTERO-LATERALI AI ABDOMENULUI

MUSCHII SPATELUI

- TRAPEZ
- MARELE DORSAL (latissimus dorsi)
- ROMBOID MIC
- ROMBOID MARE
- RIDICATOR AL SCAPULEI (levator scapulae)
- DINTAT POSTERIOR

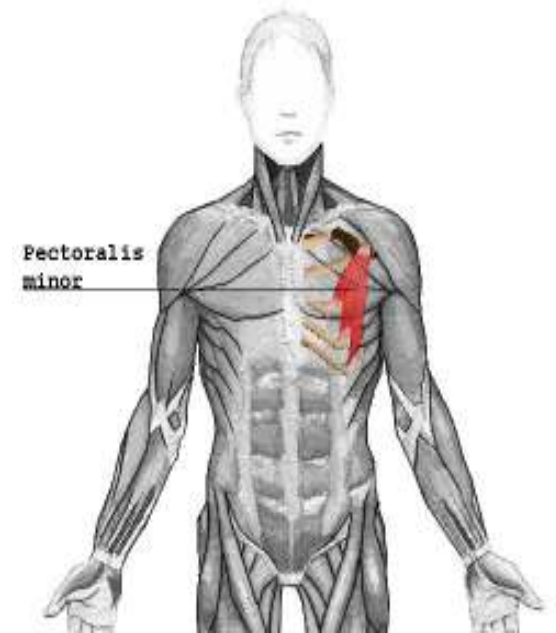
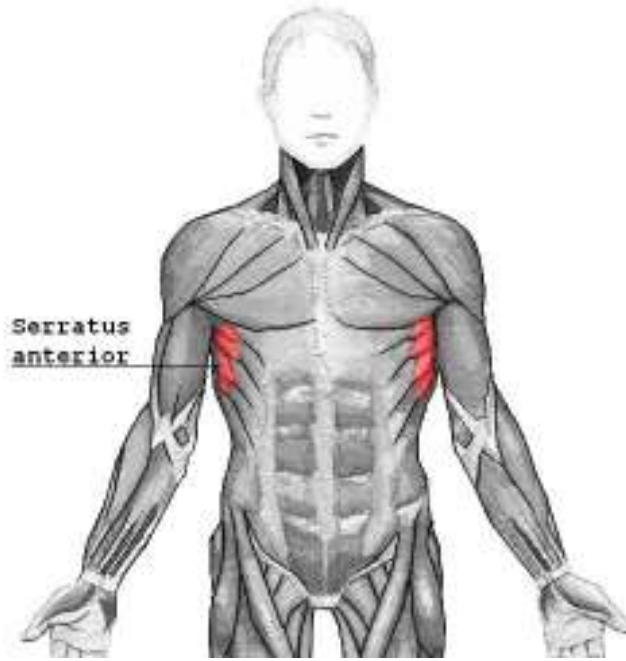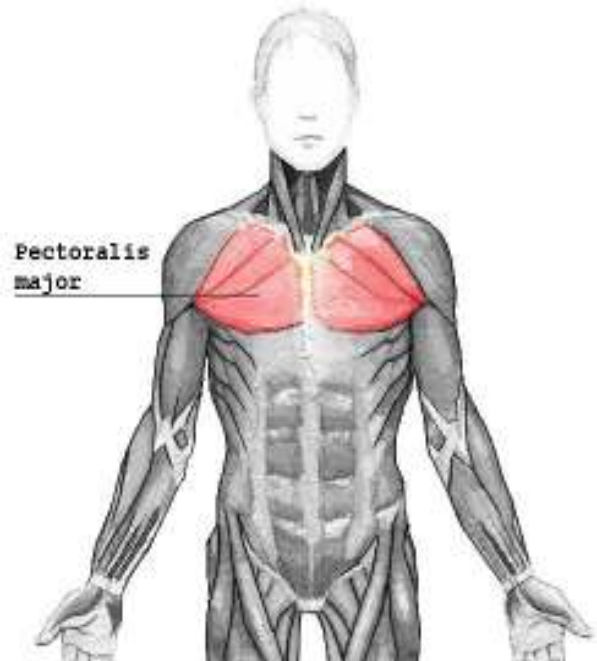
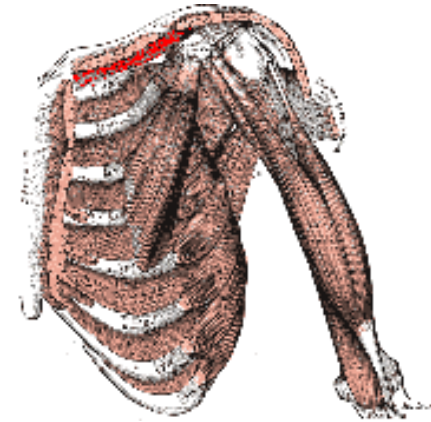


MUSCHII SPATELUI

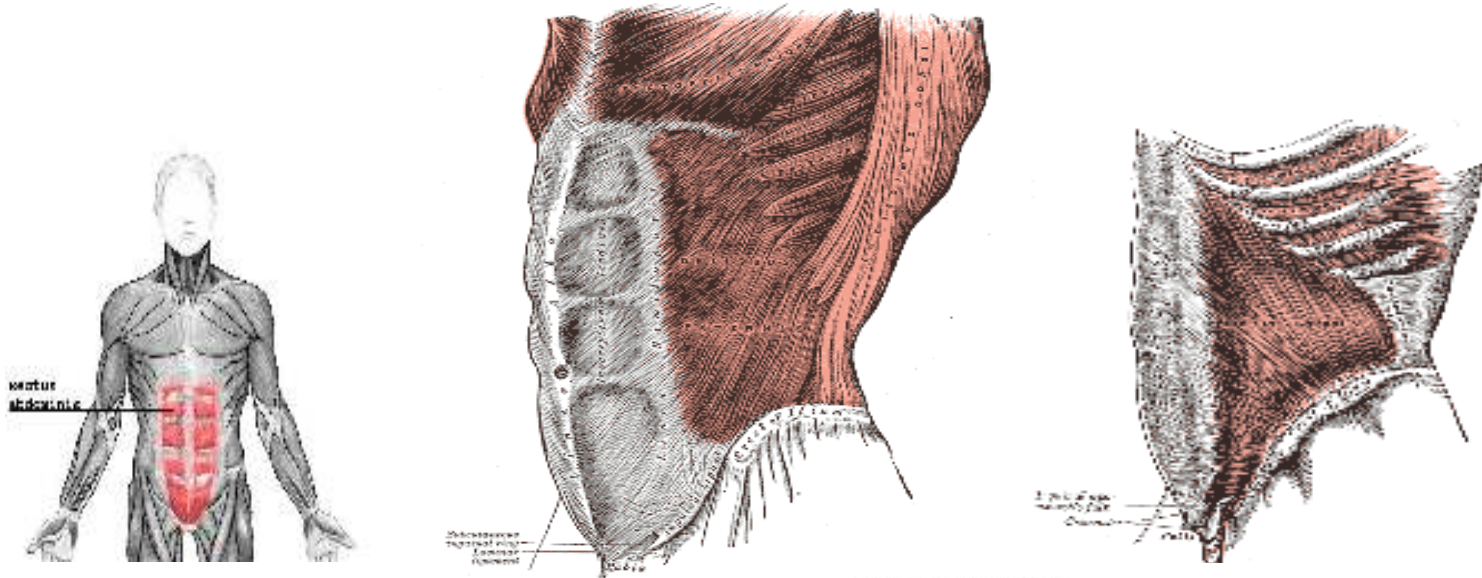


MUSCHII TORACELUI

- PECTORAL MARE
- PECTORAL MIC
- SUBCLAVICULAR
- DINTATUL ANTERIOR
- INTERCOSTALI

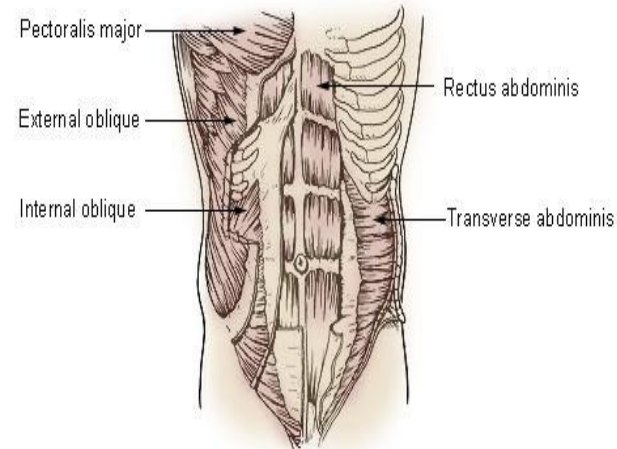


MUSCHII ABDOMENULUI



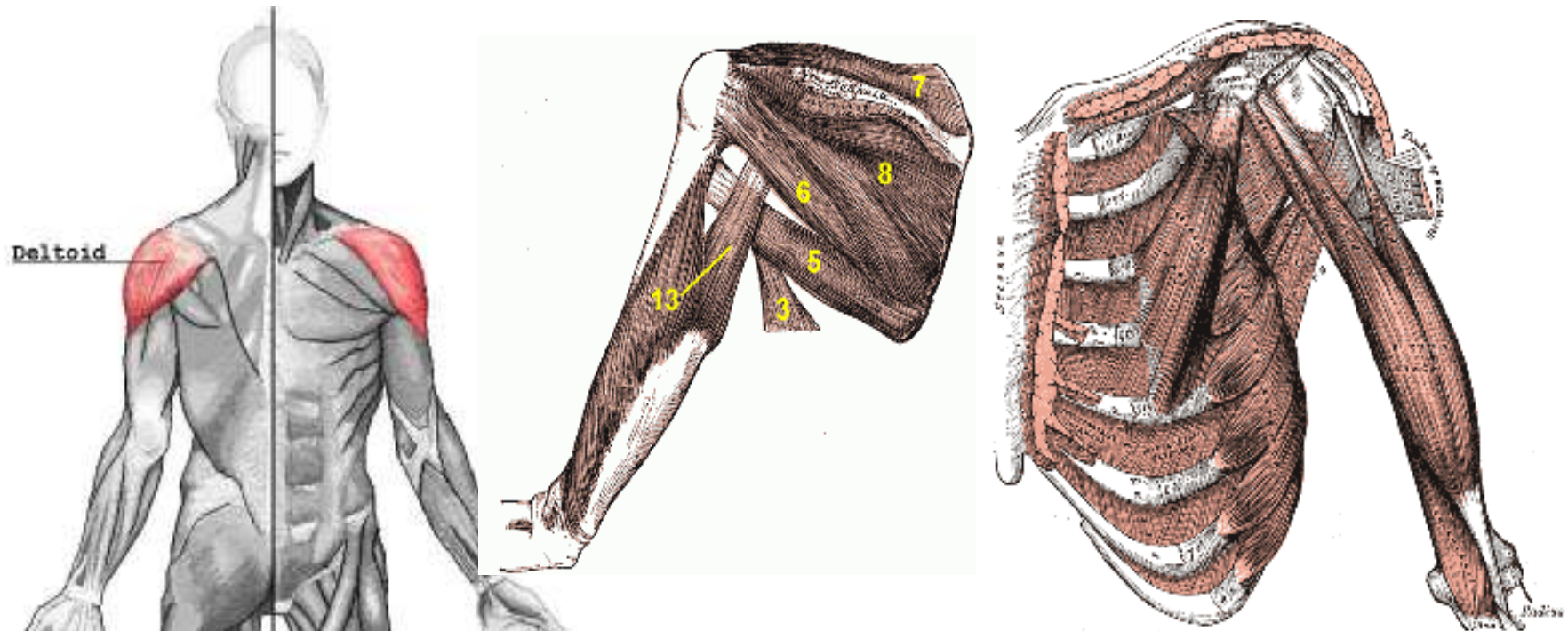
Muscles of the Trunk

- MARELE DREPT ABDC
- OBLIC EXTERN
- OBLIC INTERN
- TRANSVERS ABDOMIN



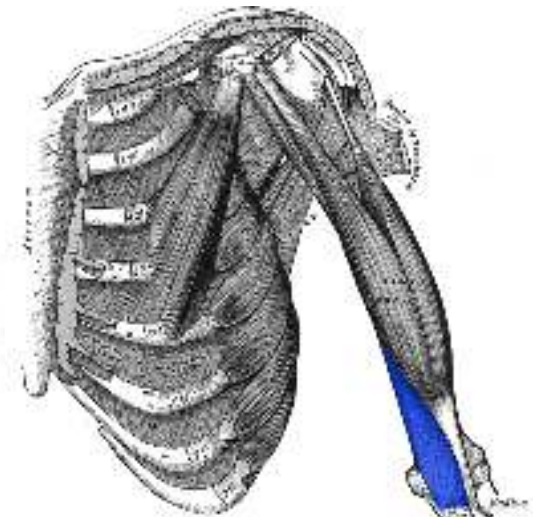
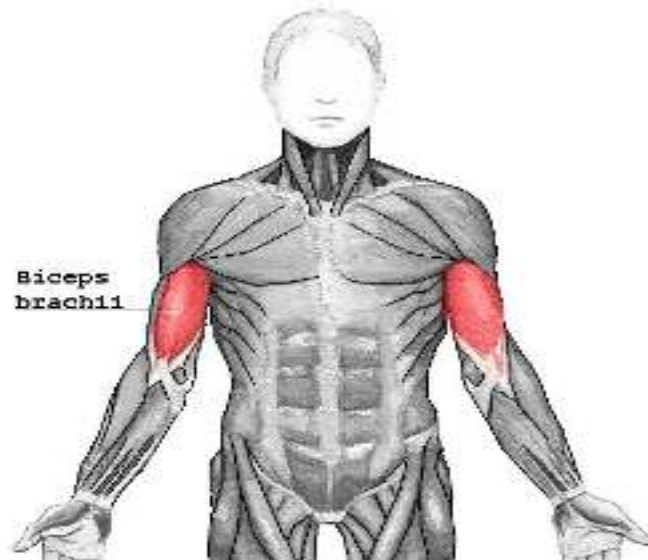
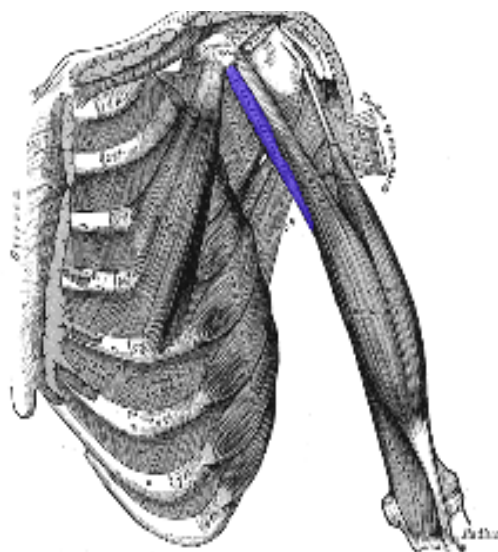
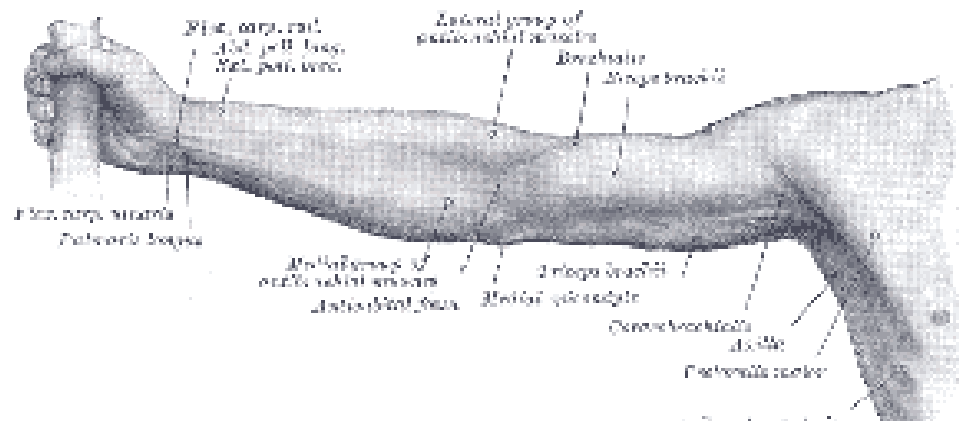
MUSCHII UMARULUI.

- DELTOID
- “COAFA ROTATORILOR” - SUPRASPINOS (7), INFRASPINOS(8), SUBSCAPULAR, ROTUND MIC(6)
- ROTUND MARE (5)

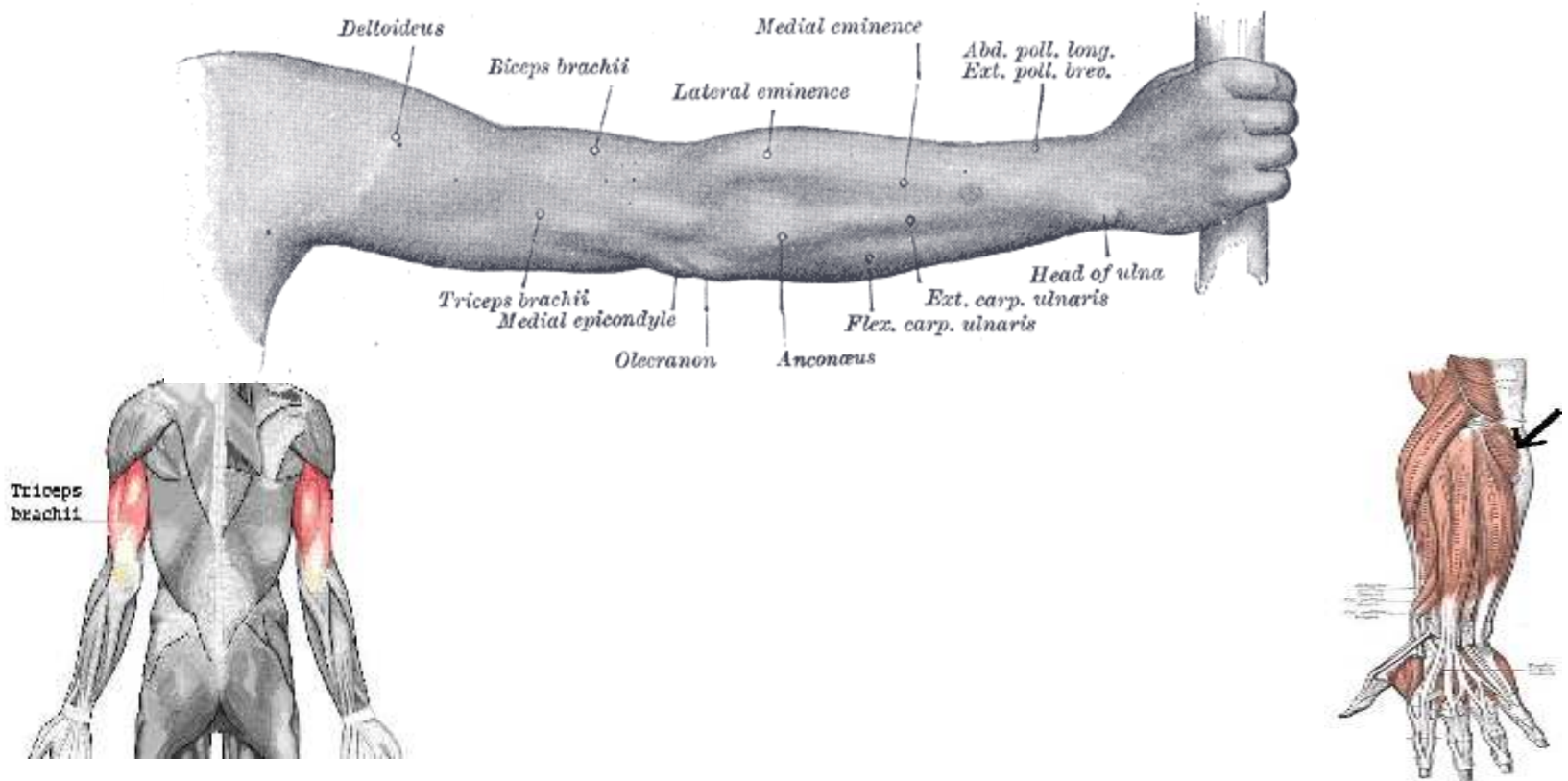


BRAT

compartment anterior
coracobrahial - biceps brahial - brahial

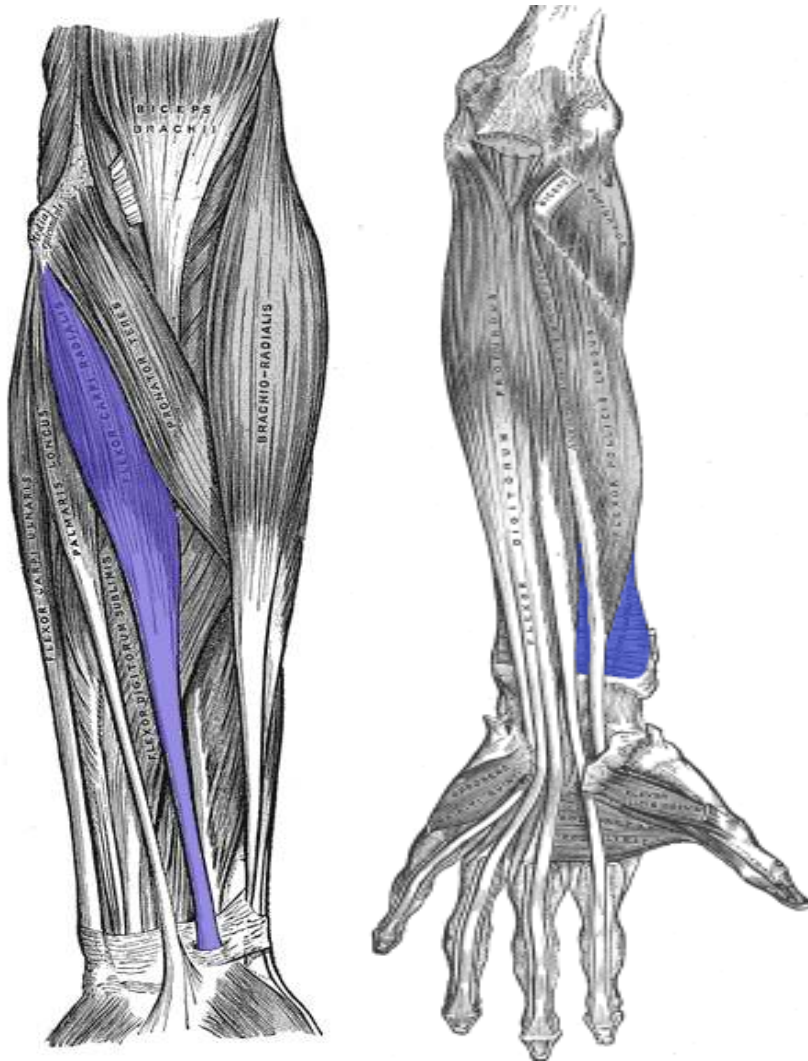


BRAT compartment posterior triceps brahial - anconeus



ANTEBRAT

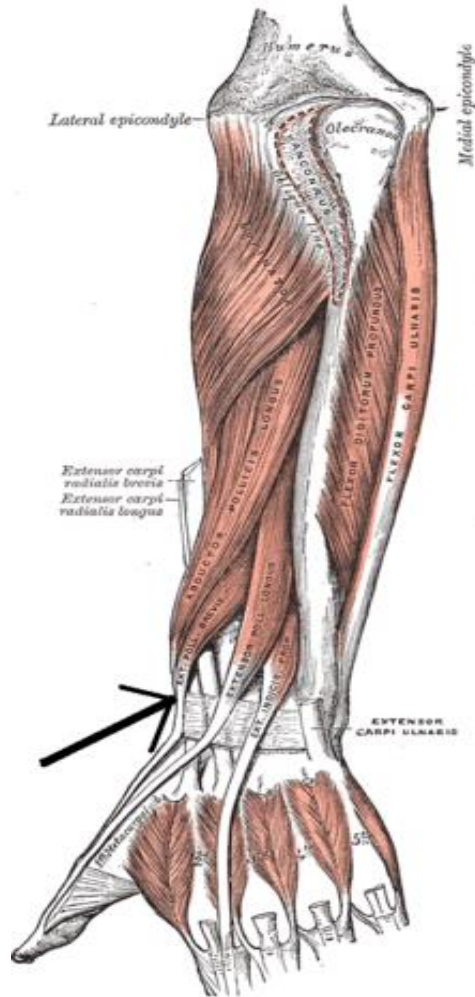
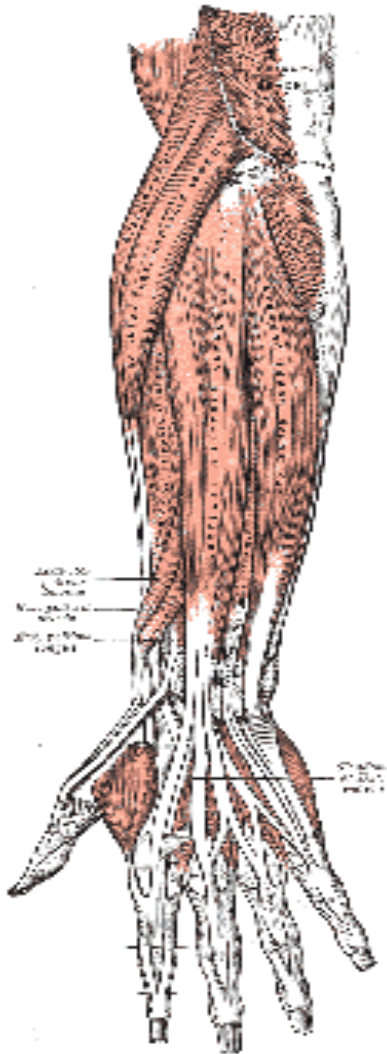
compartiment anterior



- *Superficiali*
 - rotund pronator
 - palmar lung
 - flexor radial
 - flexor ulnar
 - flexor superficial al degetelor
- *Profunzi*
 - patratul pronator
 - flexor profund al degetelor
 - flexor lung al policelui

ANTEBRAT

compartiment posterior

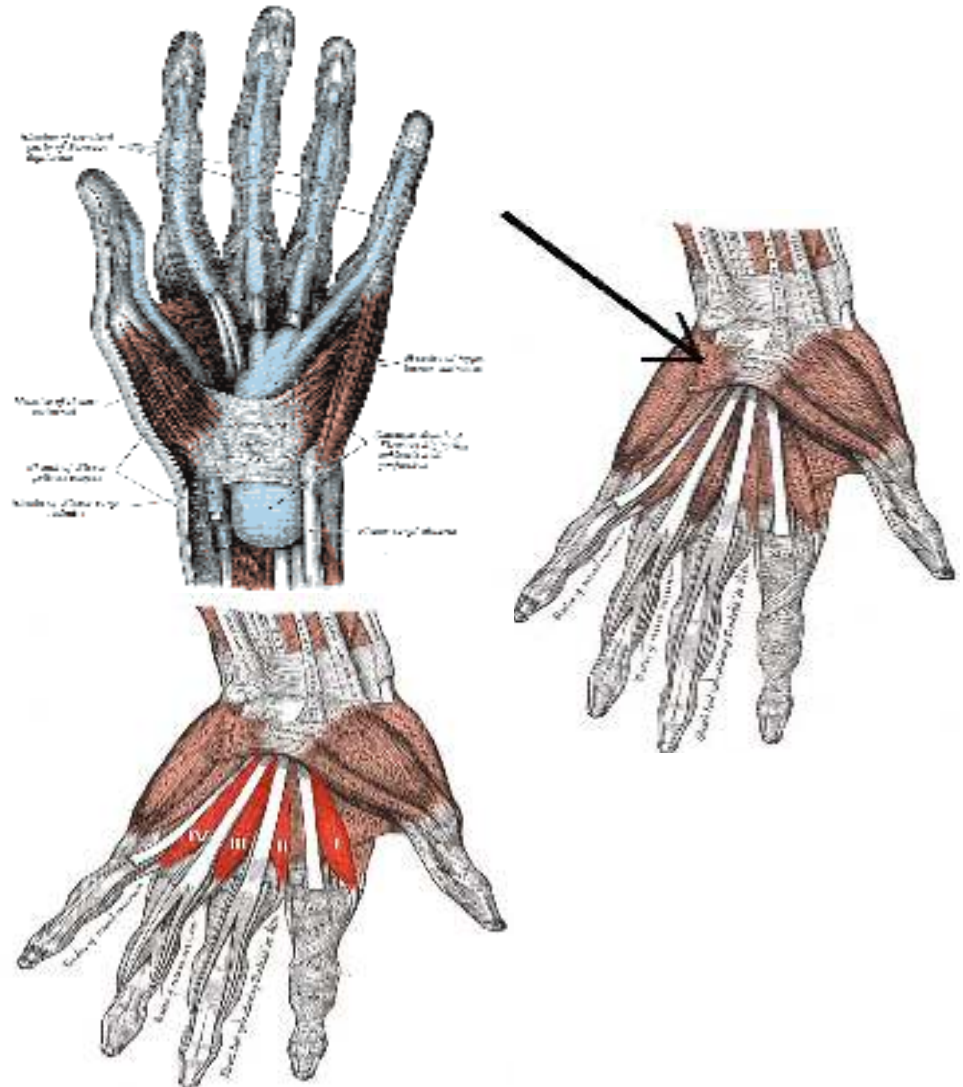


- *Superficiali*
 - brachioradiali
 - extensor radial lung
 - extensor radial scurt
 - extensor al degetelor
 - extensor al degetului mic
 - extensor ulnar
- *profunzi*
 - supinator
 - abductor lung al policelui
 - extensor scurt al policelui
 - extensor lung al policelui
 - extensor al indicelui

MANA

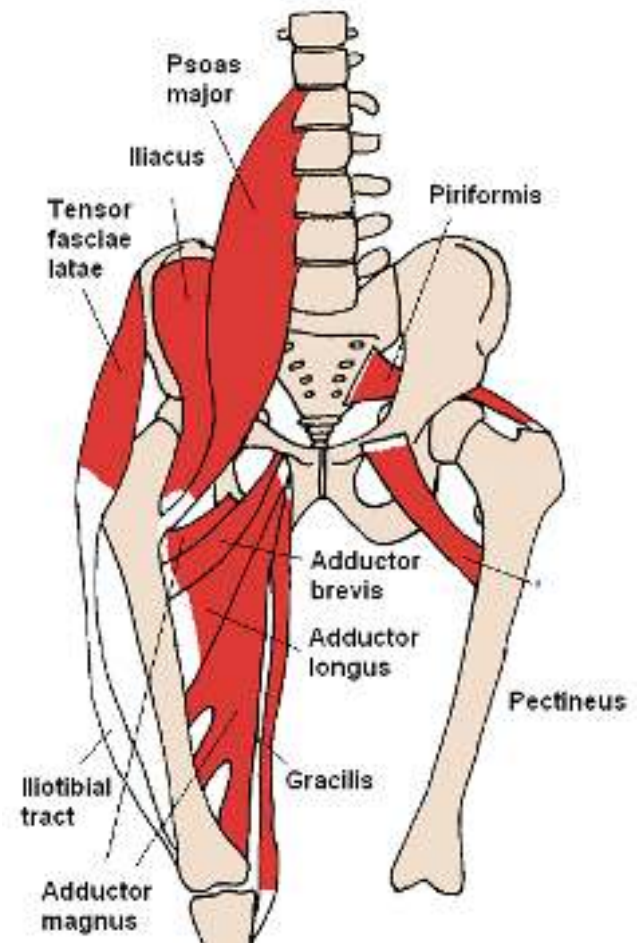
sunt exclusiv palmari

- Palma laterala – muschii eminentei tenare
 - Opozant al policelui
 - Flexor scurt al policelui
 - Adductor al policelui
 - Adductor scurt al policelui
- Palma mediala – muschii eminentei hipotenare
 - *Abductor al degetului mic*
 - *Flexor scurt al degetului mic*
 - *Opozant al degetului mic*
- Plama intermediara
- *Lumbricali*
- *Interososi dorsali*
- *Interososi palmari*



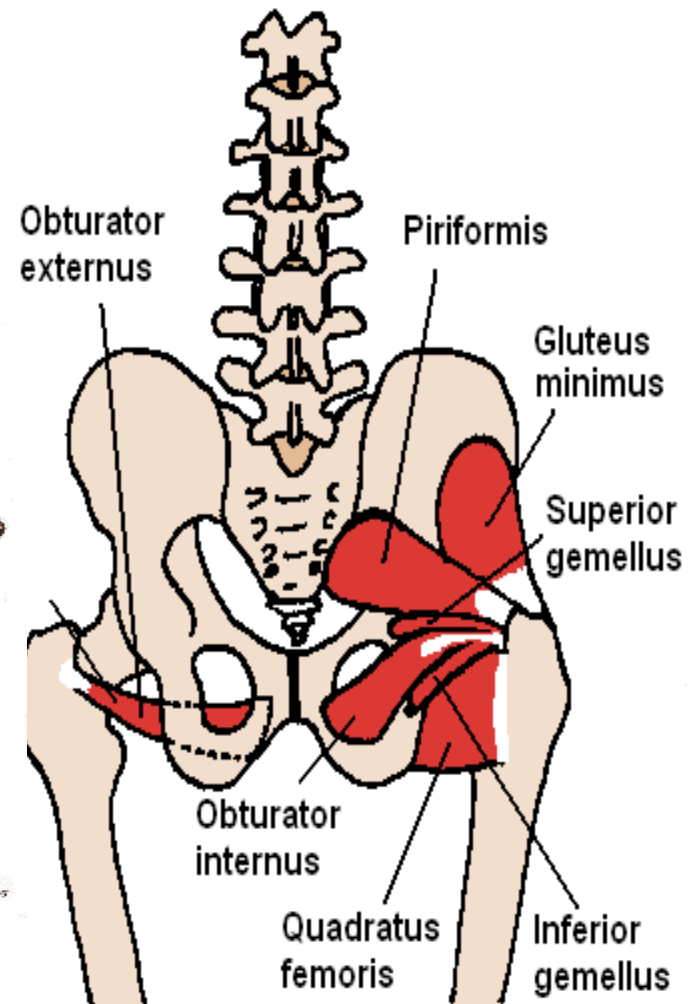
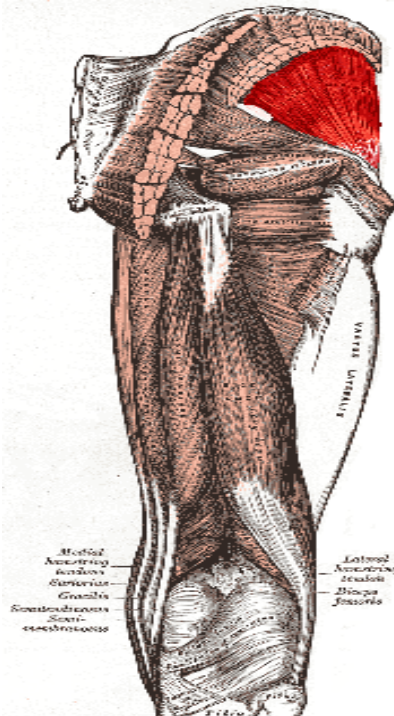
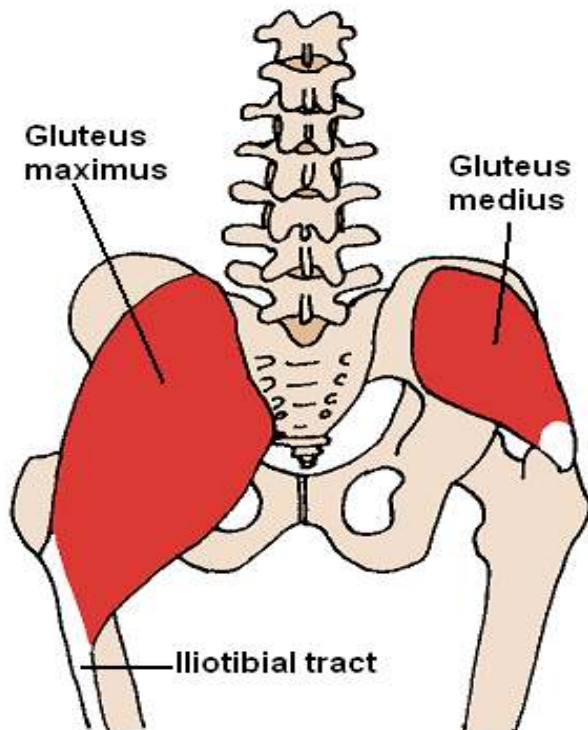
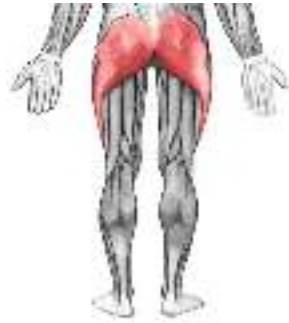MUSCHII BAZINULUI

- ANTERIORI
 - ileopsoas
- POSTERIORI



MUSCHII POSTERIORI AI BAZINULUI

- FESIERI
- OBTURATORI
- GEMENI
- PIRIFORM
- TENSOR AL FASCIEI LATA

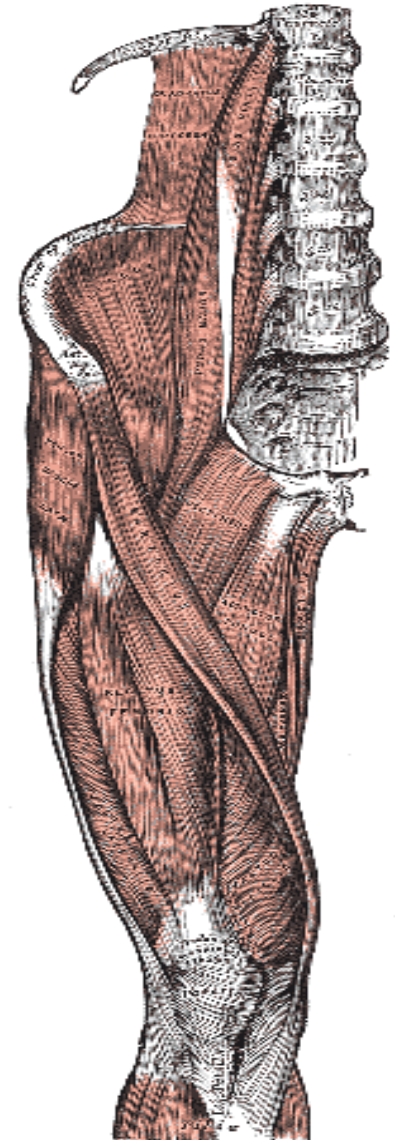
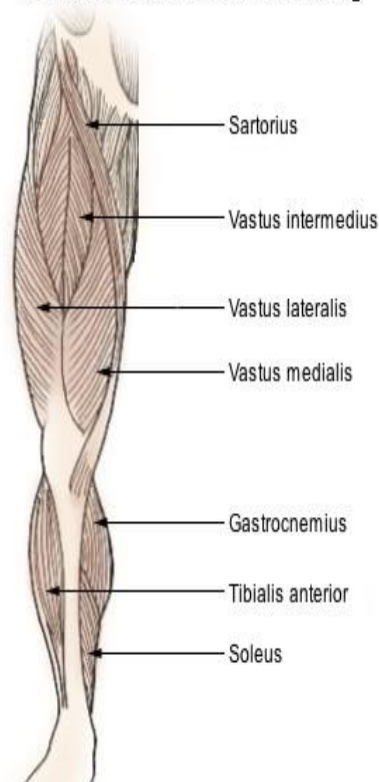


MUSCHII COAPSEI

regiunea anterioara

- CROITOR
 - cel mai lung muschi al corpului
- CVADRICEPS FEMURAL
 - are patru capete de origine

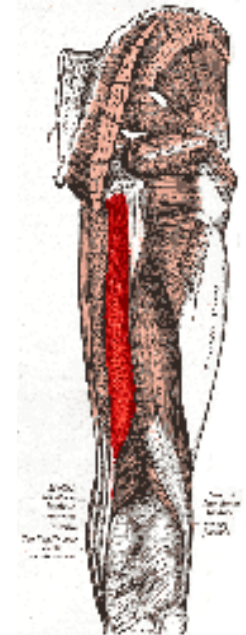
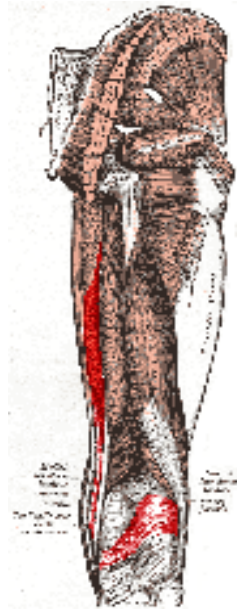
Muscles of the Lower Extremity



MUSCHII COAPSEI

regiunea posterioara

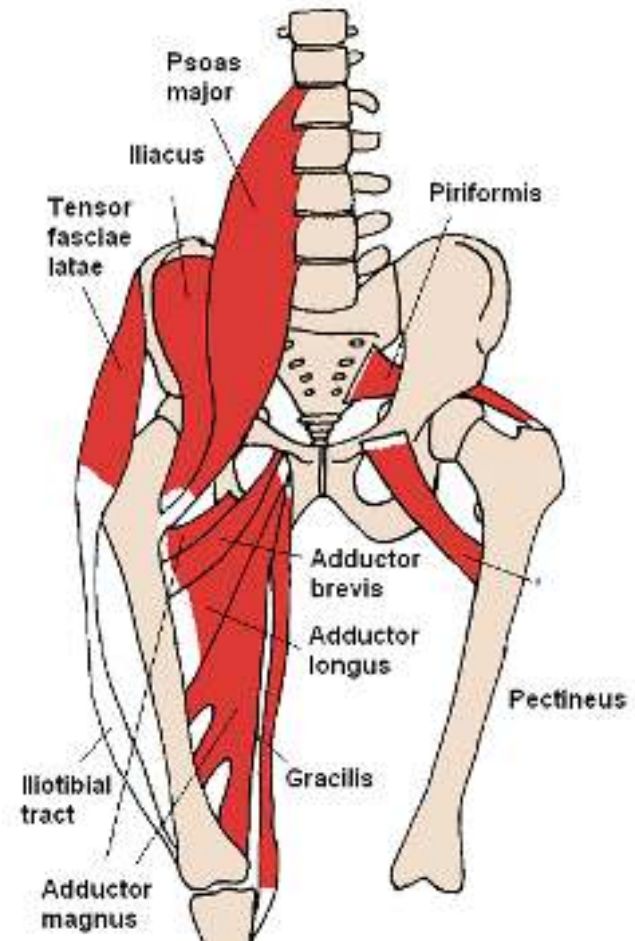
- Biceps femural
- Semimembranos
- Semitendinos



MUSCHII COAPSEI

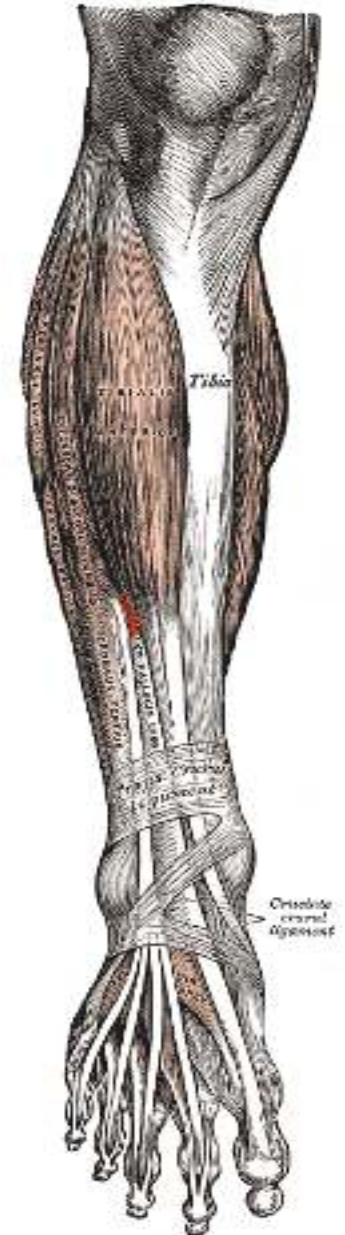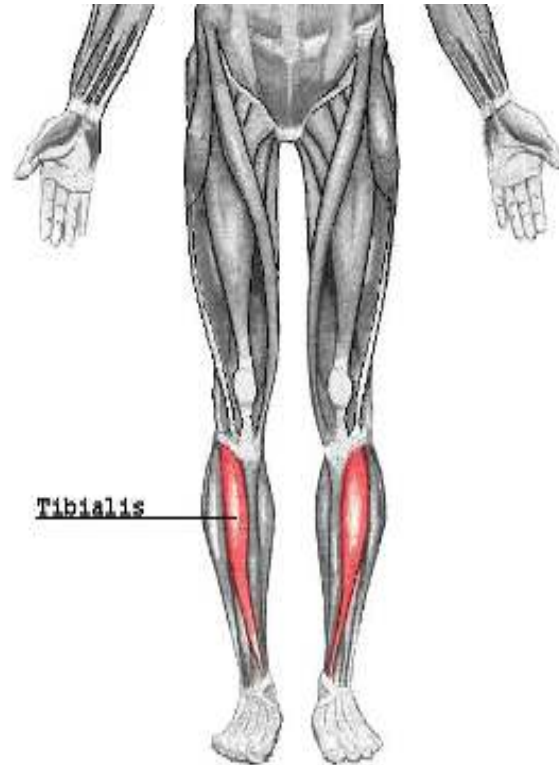
regiunea mediala

- ADDUCTORI (mare, lung, scurt)
- PECTINEU
- GRACILIS



MUSCHII GAMBEI regiunea anterioara

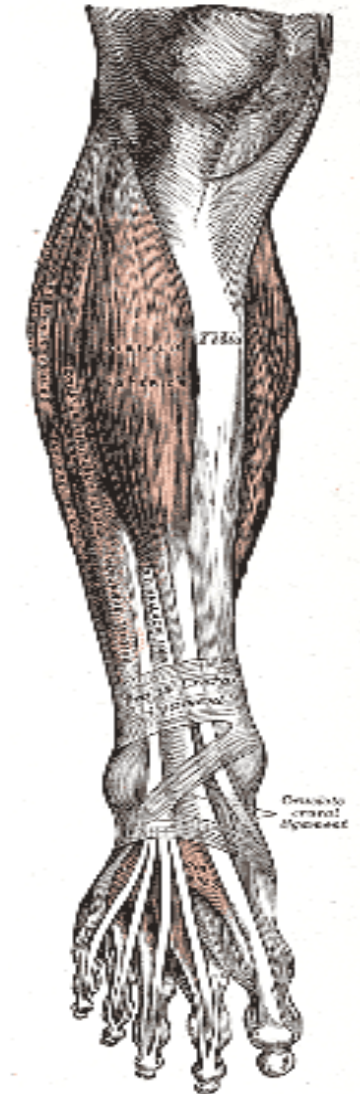
- TIBIAL ANTERIOR
- EXTENSOR LUNG
AL HALUCELUI
- EXTENSOR LUNG
AL DEGETELOR



MUSCHII GAMBEI

regiunea laterala

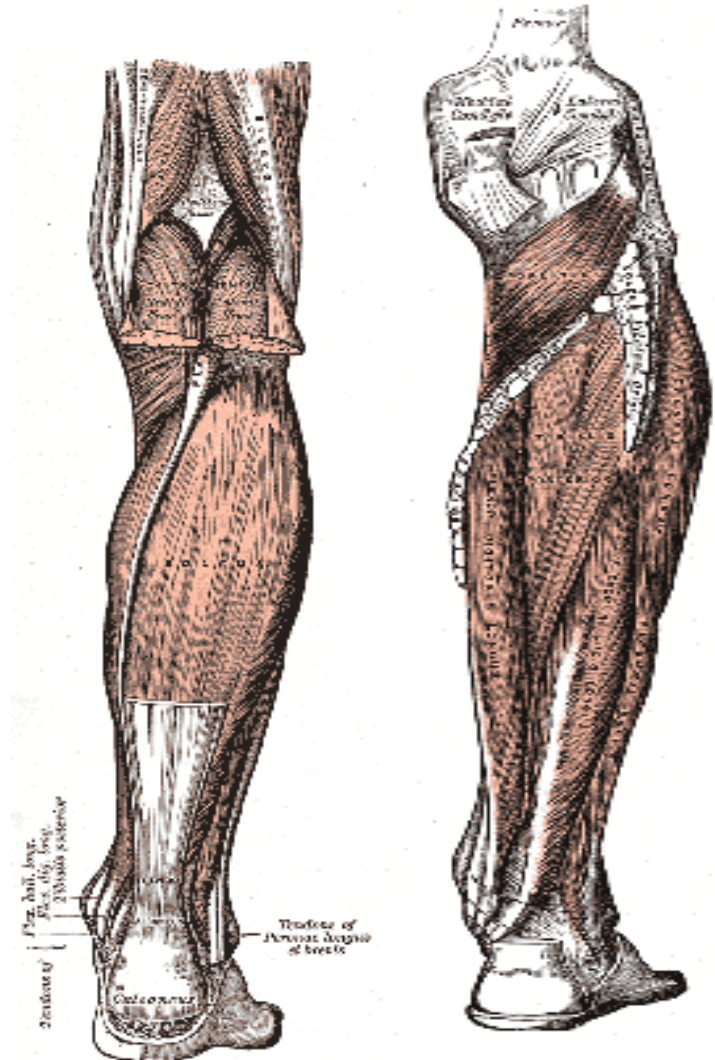
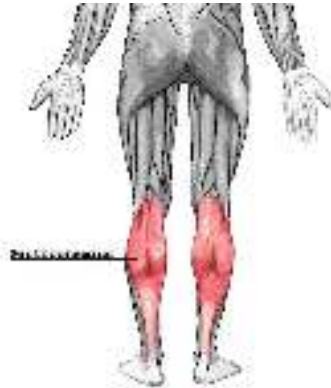- PERONIERI
 - scurt
 - lung



MUSCHII GAMBEI

regiunea posterioara

- TRICEPS SURAL
 - GASTROCNEMIAN
 - SOLEAR(se termina prin tendonul lui Achile)
- TIBIAL POSTERIOR
- POPLITEU
- FLEXOR LUNG AL DEGETELOR
- FLEXOR LUNG AL HALUCELUI



MUSCHII PICIORULUI

- Fata DORSALA
- EXTENSORI (haluce si degete)
- Fata PLANTARA
- grup medial (m. halucelui)
- grup lateral (m. degetului mic)
- grup mijlociu (m. lombricali, interososi, flexor scurt degete)

